



Ayurveda and Allopathic Therapeutic Strategies in Immune Thrombocytopenic Purpura: An Overview

© Sayali Rajendra Kale, © Pallavi Abhijit Patil

Department of Pharmacology, Bharati Vidyapeeth's College of Pharmacy, C.B.D. Belapur, Navi Mumbai, Maharashtra, India

Cite as: Kale SR, Patil PA. Ayurveda and Allopathic Therapeutic Strategies in Immuno Thrombocytopenic Purpura (ITP): An Overview. Turk J Immunol 2023;11(2):42-50

Received: 09.03.2023

Accepted: 15.05.2023

Corresponding Author: Pallavi Abhijit Patil, Department of Pharmacology, Bharati Vidyapeeth's College of Pharmacy, C.B.D. Belapur, Navi Mumbai, Maharashtra, India

Phone: +9766721459 **E-mail:** sbvp2023@gmail.com **ORCID:** orcid.org/0009-0003-7217-128X

Abstract

Idiopathic thrombocytopenic purpura (ITP) is characterized by immunologic destruction of platelets and normal/enlarged megakaryocytes in the bone marrow. ITP is broken down into acute and chronic variants. Acute forms cause significant bleeding, whereas chronic forms develop slowly and exhibit minimal to no symptoms. Body makes antibodies that are directed against its own platelets, which can lead to internal bleeding, thrombocytopenic purpura, and petechiae. Immunosuppressants, thrombopoietin receptor agonists, corticosteroids, intravenous immunoglobulins, anti-D immunoglobulin, rituximab, and splenectomy are among the treatments for chronic ITP. Around two thirds of patients benefit from existing treatments; however, some sufferers are resistant to them or do not respond to them over the long term. According to Ayurveda scriptures, ITP is related to *Tiryaga Raktapitta* because all of the Doshas are vitiated, flowing in the blood and manifesting subcutaneously.

Keywords: Immune thrombocytopenic purpura, idiopathic thrombocytopenic purpura, itp, *tiryaga raktapitta*, platelets, petechiae, autoimmune illness

Introduction

Low platelet count (thrombocytopenia) without a recognized cause is referred to as idiopathic thrombocytopenic purpura (ITP) (1). It is often referred to as immunological thrombocytopenic purpura because the majority of causes seem to be connected to antibodies against platelets. ITP is divided into acute and chronic versions based on how long it lasts (1). Following healing from an upper respiratory infection or viral infection, children are most commonly affected by the acute form of this self-restricting condition (2). The development of immunological complexes carrying viral antigens and the subsequent production of antibodies against them cause the onset of acute thrombocytopenia, which is followed by the immunologic destruction of platelets (3). Recovery takes between a few weeks and six months (4). However, chronic ITP develops slowly and lasts for a number of years in adults, especially in women of childbearing age (5). Despite

the fact that persistent ITP is idiopathic, systemic lupus erythematosus, acquired immunodeficiency syndrome, and autoimmune thyroiditis may all be associated with immunologic thrombocytopenia (6). Up to 6.4 per 100,000 children and 3.3 per 100,000 adults are affected by ITP each year. ITP is typically characterized by petechial hemorrhages, easy bruising, and mucosal bleeding, including melaena, hematuria, nasal bleeding, bleeding from the gums, and menorrhagia in females (2).

The course of untreated ITP in adults and children naturally differs from one another. In contrast to children, when it is typically followed by a viral illness, and more than 60% of individuals spontaneously achieve normal platelet counts within 6 months (7), ITP in adults typically has an insidious beginning and typically has a chronic course (8). A study by the Intercontinental Childhood ITP Study Group (ICIS-1) on more than 2,000 kids revealed that platelet counts peaked between the ages of 1 and 5 years, were under 20 10⁹/L at presentation, and were somewhat higher in boys

ORCID: S.R. Kale 0009-0001-5037-9309, P.A. Patil 0009-0003-7217-128X

(55%) than in girls (48%) (9,10). Initial administration of glucocorticoids, intravenous immunoglobulin (IVIG), or anti-D immunoglobulin (anti-D) to children may result in a faster rise in platelet count compared to no therapy (3-7). Current guidelines divide ITP into three phases depending on outcomes, which can assist in categorizing the disease's outcome: First-phase ITP is characterized by beginning within three months of the diagnosis; second-phase ITP follows is defined as appearing within the three months to one year following the diagnosis; and third-phase ITP is defined as appearing within the more than one year following the diagnosis (8-10).

An organ-specific autoimmune illness, called primary immune thrombocytopenia, is defined by a decreased peripheral blood platelet count (11). Fatigue and dry or wet purpura are the symptoms and signs, respectively (12). Though serious and life-threatening bleeding might happen, many people only experience a few or mild symptoms (13). Secondary ITP has an identifiable underlying cause, but we will not get into that here (11-13). Premature platelet destruction and relative platelet production insufficiency both contribute to the decreased peripheral blood platelet count (11). There are undoubtedly other mechanisms at work in addition to antibody-mediated platelet death, which has been known since about the 1950s (14-16). They include the inhibition of platelet formation, T-cell destruction of platelets, and T-cell-mediated death of megakaryocytes. As the underlying pathophysiology is now more known, novel therapies, including TPO-RAs, syk inhibitors, Fc receptor (FcγR) inhibition, and others, have been developed (14-16).

Pathophysiology of ITP

Abnormalities of B and T-cells

Harrington and Hollingsworth had documented the birth of a purpura-affected child in 1951 whose mother had chronic ITP (17). Three weeks later, the child's purpura disappeared, but the mother's ITP persisted. The idea that a humoral anti-platelet factor was transferred from mother to child was introduced. Harrington was given 500 mL of blood from an ITP patient to test this theory. He experienced chills, fever, headache, disorientation, and petechiae within three hours, and his platelet levels fell below $10 \times 10^9/L$ (18). He experienced four days of severely low platelet counts until it eventually started to rise by the fifth day. He repeated a similar experiment on volunteers, and the results confirmed his earlier finding (19).

Harrington's seminal work was the first to reveal that a plasma-derived component—later identified as anti-platelet antibodies—was what might have caused platelet loss in ITP. Platelet glycoproteins (GP) IIB/IIIa and Ib/

IX have been identified as the most frequently occurring antigenic targets of these autoantibodies, and many ITP patients also have antibodies against other platelet antigens (17). Clonal restriction in the use of light chains is seen in antibodies made from phage-display libraries and antibodies against GP IIB/IIIa show selective utilization of a single Ig heavy-chain variable region gene (VH3-30) (18). Antigen combining ability of these antibodies' domains have been sequenced, and these data show that somatic mutation and antigen-driven affinity selection are what gave rise to them from a small number of B-cell clones (19). It should be noted that, despite the continued presence of platelet autoantibodies, ITP can go into remission, and the autoantibodies are not detectable in up to 50% of ITP patients (20). Megakaryocytes' ability to remove autoantibodies, the presence of additional thrombocytopenia-causing pathways, and technical considerations (current monoclonal-based assays only detect antibodies with known specificity, typically GPIIb-IIIa and GPIb-IX; variable sensitivity of the assays), and the assays' variable sensitivity may all be contributing factors to these findings (20-27).

Pathogenesis of ITP

Mechanisms of cellular pathogenesis in ITP. The pathophysiology of ITP involves a variety of cells. Autoantibodies that are produced by improperly regulated megakaryocytes and platelets are damaged or destroyed in the spleen and liver when B-cells and plasma cells contact them (21). The cellular immune reaction is additionally impacted, which causes a reduction in Tregs and Bregs, enabling autoreactive plasma cells to survive (promoting the formation of autoantibodies), as well as imbalanced Th CD4⁺ T-cell subsets (22). Additionally, the activation of cytotoxic CD8⁺ T lymphocytes results in the death of Megakaryocyte (MK) and platelets as well as the disruption of bone marrow (BM) niche homeostasis (23). Therefore, ITP pathogenesis also can be explained by a deficiency in megakaryopoiesis and thrombopoiesis in addition to platelet destruction (Figure 1) (28).

Correlation of dengue with ITP

In tropical and subtropical regions of the world, dengue is a contagious viral illness (24). Dengue virus (DENV), of the genus *Flavivirus*, has four antigenically different serotypes: DENV1, DENV2, DENV3, and DENV4 (25). The *Aedes* mosquito, which infects people, is the principal vector for the virus's spread among people. Clinical manifestations range from self-limiting Dengue fever (DF) to Dengue Hemorrhagic Fever (DHF) (26). The hemorrhagic symptoms and severe thrombocytopenia that define DHF can be linked to shock and circulatory collapse (27).

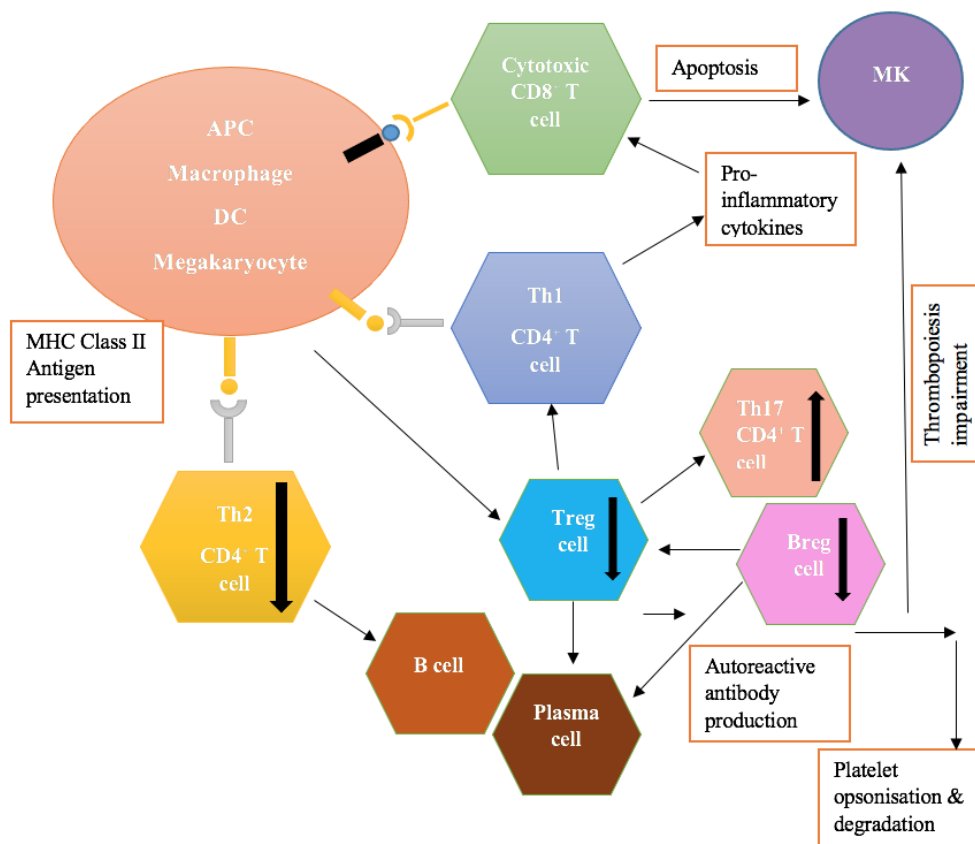


Figure 1. Pathogenesis of ITP: Mechanisms of cellular pathogenesis in immunological thrombocytopenia (ITP). The pathophysiology of ITP involves a variety of cells. Autoantibodies that are produced by improperly regulated Megakaryocytes and platelets are damaged or destroyed in the spleen and liver when B-cells and plasma cells connect to them. The cellular immune reaction is additionally impacted, which causes a reduction in Tregs and Bregs, enabling autoreactive plasma cells to survive (promoting the formation of autoantibodies), as well as imbalanced Th CD4⁺ T-cell subsets. Additionally, the activation of cytotoxic CD8⁺ T lymphocytes results in the death of MK and platelets as well as the disruption of BM niche homeostasis. Therefore, ITP pathogenesis also causes a deficiency in megakaryopoiesis and thrombopoiesis in addition to platelet destruction (28).

APC: Antigen presenting cell, DC: Dendritic cell, MK: Megakaryocyte, Th helper: T-cell

A platelet count that drops rapidly or falls below 150,000 per microliter of blood is referred to as thrombocytopenia. From day 3 of the illness, dengue infection leads to declining platelet counts, returning to normal on days 8 or 9 (28). There are several different hypothesized pathways for dengue thrombocytopenia. In the initial stages of the illness, bone marrow is suppressed (29). Marrow suppression is caused by faulty bone marrow regulation, direct DENV injury to progenitor cells, and stromal cell infection. Increasing peripheral platelet oxidation also may lead to more prominent thrombocytopenia (30). It has been proven that dengue patients contain immunoglobulin M (IgM) isotype anti-platelet antibodies (31). Antiplatelet IgM titres are generally higher in DHF than in DF, and complement activation exacerbates platelet lysis (32). According to numerous studies, DENV directly infects platelets, which triggers immune-mediated destruction (33). Dengue disease activates the coagulation and fibrinolytic pathways, which consume platelets (34). Finally, platelet dysfunction in

DENV results in altered platelet activation and aggregation. There are very few reports of persistent thrombocytopenia following dengue illness (35). In the majority of the prior instances, steroids, which were administered either as intravenous methylprednisolone or oral prednisolone, resulted in a positive outcome (36). Steroid inhibits platelet phagocytosis mediated by Fc receptors and decreases the production of anti-platelet antibodies (30-40).

Raktapitta

The amount of rakta that is vitiated by pitta grows (38). According to Raktapitta literature, as a result of *pitta's usna guna*, it begins to flow out of the body through various regions, including the skin pores or both the upward and downward directions dependent on the way that the blood is flowing (39).

The three varieties of *Raktapitta* are as follows:

a) *Urdhvaga*- Snigdha and ushna guna, which impede the interaction of kapha and pitta, are present in *Urdhvaga*.

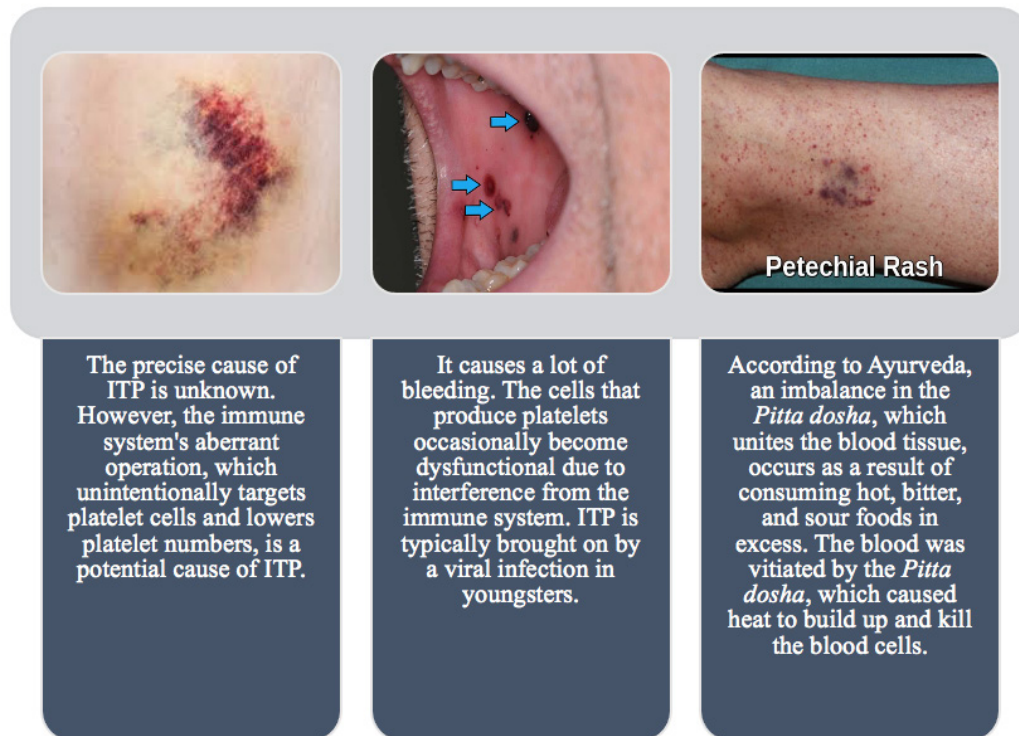


Figure 2. Causes of ITP.

ITP: Idiopathic thrombocytopenic purpura

This causes the pouring of polluted blood through upper passageways or orifices, such as the *mukha* (mouth), *Karna* (ears), *Akshi* (eyes), and *Nasa* (Nostrils) (40).

b) *Adhoga*: The characteristics of *ruksha* and *ushna guna* lead the *vata* and *pitta* to become vitiated, and polluted blood leaks out through descending orifices such as the *Guda*, *Yoni*, and *Mutramarga* (41).

c) *Tiryaka*: The subcutaneous manifestation occurs when all of the *doshas* are vitiated and moving through the bloodstream. ITP and *Tiryaga Raktapitta* are connected because both involve subcutaneous manifestation and *rakta* vitiation (2,41).

The primary functional organs in Ayurveda, which are primarily associated with the formation of *Rakta Dhatu*, are the liver and spleen (42,43). *Pitta Dosha* is undoubtedly disturbed when there is *Raktadhatu dushti* since *Rakta* and *pitta* have an *ashraya ashrayi bhav* (44). Therefore, in accordance with Ayurveda, if we need to cure *Triyak Raktapitta*, we should work with medications that affect the liver and spleen as well as medications that have *Pittadosha shamak* qualities (42).

Due to the reasons listed below, the illness is known as *Raktapitta*:

Samyogaat- Samyoga is Sanskrit for association or fusion. *Pitta* and *Rakta* are inextricably linked. Due to this relationship, *Rakta* becomes contaminated by vitiated *Pitta*.

Dooshanaat- Dooshanaat is an Arabic word that indicates a propensity to taint or vitiate. *Samyoga* between *Pitta* and *Rakta* has the tendency to vitiate the *Rakta*.

Saamaanyaad Gandha Varnayoho- By achieving similarities with *Rakta* in terms of *Gandha* (odour) and *Varna*, *Varnayoho-Pitta* (colour) (45). For example, in *Raktapitta*, the *Pitta's* color and scent cannot be distinguished independently since it is combined with more *Rakta* to take on the shape of *Rakta*. As a result, the vitiated *Pitta* and *Rakta* acquire homologues. The illness is known as *Raktapitta* because *Pitta* (not being diagnosed or isolated) is mixed with *Rakta* seems to belong to *Rakta* inseparably (*RaktasyaPittam*) (43).

Diagnosis of ITP

ITP is often diagnosed through the inspection of the peripheral smear, evaluation of the patient's history, and physical examination (46). All ITP patients should undergo a few extra tests, including blood type, HIV, hepatitis C, and tests for *H pylori*, HIV, and hepatitis C (47). Except for *H pylori* testing, the ASH guidelines advise similar testing for individuals with ITP (only recommended for some geographic areas and if treatment of eradication is possible) (48). In contrast to the ASH guidelines, which are backed by some demographic studies, the IWG advises performing bone marrow exams in patients who are >60 years old with newly diagnosed ITP. In individuals with uncomplicated,

recently diagnosed ITP, additional “screening” testing for immunodeficiency (including immunoglobulin levels) and other autoimmune diseases is rarely beneficial in the absence of symptoms (49). In fact, a positive antinuclear antibody in the absence of other indications of autoimmune illness is rarely a predictor of the development of another disease (50). Although some research in children have indicated that a positive antinuclear antibody may be linked to an increased risk of chronic or refractory disease, studies in adults are few and do not clearly show a link with treatment response or chronicity (44-48).

Treatment

Initial Therapy

In adult patients without symptoms, the first treatment for newly diagnosed ITP is advised at a platelet count of 20 to 30 $10^9/L$ (51). The specialists suggested that each patient’s treatment objectives be unique, with a focus on preventing bleeding in addition to limiting toxicity and improving quality of life.

Corticosteroids: Unless there is a contraindication for corticosteroid usage or a need for a faster platelet rise due to severe bleeding, this is the preferred first-line treatment for persons with chronic ITP (52). For 2-3 weeks, prednisone oral solution, 0.5-2 mg/kg/day, should be administered with the goal of stopping in 6-8 weeks (53). Although relapse rates are high and rates of sustained remission are poor, the first response rates are typically between 70 and 80% (54). To deliver a greater total amount of corticosteroid over a shorter exposure period, dexamethasone has also been recommended at larger dosages (40 mg each day for four days) (55). There was no difference between the long-term response rates and the overall platelet response at 6 months (54% vs. 43%, $p=0.44$) in a systematic review and meta-analysis of nine randomized studies ($n=1.138$) comparing high-dose dexamethasone with oral prednisone. In contrast, the dexamethasone group saw fewer adverse events (24% vs. 46%) and a greater total platelet response (79% vs. 59%, $p=0.048$) in 14 days. While both types of corticosteroids are effective, the best course of treatment should depend on the patient’s preferences, side effect profiles, and requirement for a quick recovery (13,49-52).

IVIg: Since its efficacy in treating ITP was first established in 1981, IVIG has been routinely utilized as first-line anti-ITP therapy with or without corticosteroids (13). There are numerous and complex mechanisms for the explanation of the effect of IVIG administration. IVIG is hypothesized to prevent the reticuloendothelial system’s Fc-mediated phagocytosis of antibody-coated platelets (56). Commonly advised doses are 0.4 g/kg/day for up to 5 days or 1 g/kg/day for 1-2 days (high dose) (low-dose) (57). For acute ITP, a meta-analysis of 13 randomized studies

found no statistically significant difference in efficacy between IVIGs at high and low doses (58). Low-dose IVIG was also associated with a reduced risk of adverse effects, such as fever, nausea, and vomiting (53-55).

Immunoglobulin that is against to the D antigen of the Rh blood grouping system is known as anti-D immunoglobulin.

It works by preventing the destruction of antibody-coated platelets by competing with anti-D-coated erythrocytes for Fc receptors on macrophages (59). Hence, it is only effective in Rh-positive patients with an intact spleen (60). Typically, one intravenous infusion at a dose of 50 to 75 g/kg was advised, and the reaction happened within 48 hours (61). The overall response rate is 65% and typically lasts for 3-4 weeks (62). Anti-D immunoglobulin therapy has main drawback of severe intravascular hemolysis, which can be fatal, as it has been well described despite an extremely rare occurrence (56-60).

Second Line Therapy

Most ITP patients react to basic therapy, such as glucocorticoids or IVIG, although many patients eventually need secondary therapy since it is challenging to maintain long-term responses (63-65). Medical treatment (TPO-RA, rituximab) or surgery (i.e. splenectomy) may be options for select patients.

Thrombopoietin receptor agonists: Small molecules called TPO-RAs encourage thrombopoietin to boost platelet synthesis by megakaryocytes in the bone marrow (66,67). The U.S. Food and Drug Administration has currently approved three agents (Eltrombopag, Romiplostim, and Avatrombopag) for the treatment of chronic ITP (68,69). Although long-term remission following TPO-RA treatment has been observed in about 15% of cases, the total response rate of TPO-RA is estimated to be between 60 and 90%, and it is not usually believed to be curative (61-66).

Rituximab: As B-cells are crucial in the pathogenesis of ITP, rituximab, a chimeric monoclonal antibody targeting CD20 on the surface of B-lymphocytes, has been suggested as a therapy option for ITP for many years (70-72). To prevent treatment-related side effects, the efficacy and safety profiles of low-dose rituximab (100 mg or 100 mg/ $m^2/week$ for 4 week) were also investigated. According to a comprehensive analysis, patients with ITP who received low-dose rituximab had a pooled overall response rate and complete response rate of 63% and 44%, respectively (73,74). The effectiveness and safety profile of low-dose rituximab treatment is satisfactory (67-71).

Splenectomy: With a splenectomy, roughly 70-80% of patients experience sustained CR lasting more than six months, and 60-70% of patients exhibit maintained response over five years (75). The decline in choice is being driven by both the increasing availability of efficient

non-surgical treatment alternatives and concerns related to potential issues arising from medical procedures (76). Due to fewer operational problems (0.2% vs. 1%), laparoscopic splenectomy is preferred over open splenectomy (77). Moreover, splenectomy raises the risk of sepsis by 2.1% and the risk of venous thromboembolism by 2-4 times (78). Due to high probability of surgical complications and the possibility of spontaneous ITP remission within the first year, splenectomy should only be considered if chronic ITP has been confirmed (72-77).

The treatment approach for ITP depends on the severity of its symptoms (78). ITP is naturally treated with Ayurveda. The main causes of all diseases, according to Ayurveda, are a sedentary lifestyle and an unhealthy diet. To alleviate symptoms and issues, Ayurveda emphasizes dietary and lifestyle changes. Herbs are also offered as a natural, side-effect-free means of treating disease. Several herbs that control immune response and raise the body's platelet count can also be used to treat ITP. In order to manage ITP condition, the patient is also provided a customized nutrition plan. These herbs' primary goal is to lessen inflammation and pain brought on by ITP.

The following are the numerous plants that can be used to treat sickness naturally:

1. Giloy

Botanical name: *Tinospora cordifolia*

In Ayurveda, the Giloy plant has a reputation for being exceedingly potent. It has antibacterial, anti-inflammatory, and anti-allergic effects. The Vata and Pitta doshas, which are closely related to ITP, are balanced by this plant. Giloy juice is made from the Giloy stems. It raises the platelet count and improves the body's capacity to fight with foreign invaders. As a result, it is a particularly effective plant for treating ITP.

2. Ashwagandha

Botanical name: *Withania somnifera*

Through better immune system performance, this herb aids in increasing platelet levels. Along with platelet cells, ashwagandha boosts the production of white, red, and blood cells. It reduces the body's ability to suppress the immune system. Additionally, this herb supports a healthy body, lowers stress levels, and increases stamina.

3. Noni

Botanical name: *Morinda citrifolia*

In ITP patients, this herb helps to lessen bleeding issues. It has numerous qualities, including analgesic, immunomodulator, anti-inflammatory, and antioxidant activities.

4. Curcumin

Botanical name: *Curcuma longa*

The turmeric herb is used to make the curcumin pill (*Curcuma longa*). Turmeric contains the active ingredient curcumin. It works well for ITP because it helps the body get rid of impurities and purifies the blood. The herb also has a variety of other qualities, including analgesic, immunomodulator, anti-inflammatory, and antioxidant.

5. Papaya

Botanical name: *Carica papaya*

ITP can be effectively treated with papaya leaf extract. It aids in raising the body's platelet counts.

6. Aloe Vera

Botanical name: *Aloe barbadensis*

Aloe Vera relieves the symptoms of ITP and aids in boosting platelet count. Juice from Aloe Vera reduces mouth and gum bleeding.

Additionally, several traditional Ayurvedic formulations including *Pitta Balan*, *Kumar Kalyan Ras*, and immune-boosters are utilized to treat ITP.

- *Pishti Akika* (powder of the agate gemstone) - According to the traditional texts of Ayurveda, the first therapy option is *Akika Pishti*, or powdered agate gemstone treated with *Gulab* (rose water), *Ketaki* (umbrella tree flower), and *Chandana* (sandalwood).
- It has traditionally been recommended for use in the treatment of *Rakta pradara*, bleeding gums, *Rakta pitta*, *Raktasrava*, and *Rakta shtivana*, which are illnesses connected to acidity.
- Quartz stone or pure crystal, *Shuddha Sphatika* - Few patients are advised to use *Shuddha Sphatika*, or pure crystal or quartz stone.
- *Raktastambhana* (bleeding-prevention) and *Sankochna* (narrowing) characteristics. *Sharkara* (Sugar) (Sugar) Sugar, or *Sharkara*, possesses *Rasayana* and *Bala* qualities. It boosts immunity and lessens platelet deterioration.
- *Durva* (herbal grass) (herbal grass) - External healing can be accomplished with *Durva* or herbal grass and aids in reducing blood loss from wounds. It is used to treat conditions like wounds, burning sensations like erysipelas and urticaria, and skin depigmentation.
- In addition to these main components, numerous additional herbs with *Rakta pitta shamak* (acidity-calming) qualities are employed to boost the body's energy and immunity. These include plants that help produce red blood cells (erythropoietin properties) (29).
- Numerous herbs contain oligospirostanoside, which is thought to be a potent immunoside with anti-inflammatory properties (29).

Ayurvedic Treatment of ITP vs. Allopathic Treatment

Patients receiving ITP treatment in modern medicine typically receive the two most popular forms of urgent care: dexamethasone and intravenous gamma globulin (IVGG).

Steroids: They stop bleeding by slowing down the degradation of platelets, which raises platelet levels that can be seen in 2 to 3 weeks. Long-term adverse effects could include liver failure, heart attack, etc. whereas short-term negative effects could include stomach irritability, weight gain, high blood pressure, and acne.

IVGG is an antibody-containing protein that also inhibits the oxidation of platelets. Within 24 to 48 hours, IVGG demonstrates an increase in platelet count. In contrast to its major side effects, which include renal failure, thrombosis, arrhythmia, aseptic meningitis, hemolytic anemia, and transfusion-related acute lung injury, side effects may include flushing, headache, malaise, fever, chills, weariness, and lethargy. External Ayurvedic treatments like *Snehapana* and *Virechana* are administered; its adverse effects are restricted to exhaustion, vomiting, loose stools, and temporary loss of appetite. Ayurvedic medications including *Durwa*, *Amlaki*, *shatavari*, ashwagandha, and *gokshura*, among others, have anticoagulant and antineoplastic properties that aid patients in recovering from ITP. Until and unless they are delivered incorrectly, ayurvedic medications for the treatment of ITP are fully natural and do not have any significant negative effects after long-term use (78).

Conclusion

It is clear from this review that ITP is a complicated disease. Emerging findings on the use of second-line medicinal therapy to manage individuals needing pharmacologic intervention have led to a decline in the rate of splenectomy since the creation of guidelines for the diagnosis and management of ITP. The use of second-line medicines to reduce risks and adverse effects while offering treatment alternatives with fair likelihood of success has advanced beyond those published standards, even though clinical practice is still lagging behind them in terms of adhering to diagnostic evaluations. ITP is treated with an anticoagulant and antineoplastic strategy in Ayurveda. Hence Allopathic and Ayurvedic, both treatments may serve to manage or treat ITP.

Peer-review: Externally peer-reviewed.

Authorship Contributions

Concept: S.R.K., P.A.P., Design: S.K., P.A.P., Data Collection or Processing: S.R.K., P.A.P., Literature Search: S.R.K., P.A.P., Writing: S.R.K., P.A.P.

Conflict of Interest: No conflict of interest was declared by the authors.

Financial Disclosure: The authors declared that this study received no financial support.

References

1. Harsh Mohan textbook of pathology, by Harsh Mohan, published by Jaypee Brothers medical publishers (P) Ltd New Delhi, Sixth Edition, Chapter 2010;13:332.
2. Terrell DR, Beebe LA, Vesely SK, Neas BR, Segal JB, George JN. The incidence of immune thrombocytopenic purpura in children and adults: A critical review of published reports. *Am J Hematol.* 2010;85:174-80.
3. Palau J, Jarque I, Sanz MA. Long-term management of chronic immune thrombocytopenic purpura in adults. *Int J Gen Med.* 2010;3:305-11.
4. Stasi R, Stipa E, Masi M, Cecconi M, Scimò MT, Oliva F, et al. Long-term observation of 208 adults with chronic idiopathic thrombocytopenic purpura. *Am J Med.* 1995;98:436-42.
5. Kühne T, Imbach P, Bolton-Maggs PH, Berchtold W, Blanchette V, Buchanan GR; Intercontinental Childhood ITP Study Group. Newly diagnosed idiopathic thrombocytopenic purpura in childhood: an observational study. *Lancet.* 2001;358:2122-5.
6. Segal JB, Powe NR. Prevalence of immune thrombocytopenia: analyses of administrative data. *J Thromb Haemost.* 2006;4:2377-83.
7. Blanchette VS, Luke B, Andrew M, Sommerville-Nielsen S, Barnard D, de Veber B, et al. A prospective, randomized trial of high-dose intravenous immune globulin G therapy, oral prednisone therapy, and no therapy in childhood acute immune thrombocytopenic purpura. *J Pediatr.* 1993;123:989-95.
8. Găman MA, Găman AM. Pathophysiology, diagnosis and treatment of immune thrombocytopenia. *International Journal of Medical Students.* 2017;5:32-6.
9. Audia S, Mahévas M, Samson M, Godeau B, Bonnotte B. Pathogenesis of immune thrombocytopenia. *Autoimmun Rev.* 2017;16:620-32.
10. Tärniceriu CC, Hurjui LL, Florea ID, Hurjui I, Gradinaru I, Tanase DM, et al. Immune thrombocytopenic purpura as a hemorrhagic versus thrombotic disease: an updated insight into pathophysiological mechanisms. *Medicina (Kaunas).* 2022;58:211.
11. Provan D, Semple JW. Recent advances in the mechanisms and treatment of immune thrombocytopenia. *EBioMedicine.* 2022;76:103820.
12. Cines DB, Blanchette VS. Immune thrombocytopenic purpura. *N Engl J Med.* 2002;346:995-1008.
13. Provan D, Arnold DM, Bussell JB, Chong BH, Cooper N, Gernsheimer T, et al. Updated international consensus report on the investigation and management of primary immune thrombocytopenia. *Blood Adv.* 2019;3:3780-817.
14. Harrington WJ, Minnich V, Hollingsworth JW, Moore CV. Demonstration of a thrombocytopenic factor in the blood of patients with thrombocytopenic purpura. *J Lab Clin Med.* 1951;38:1-10.
15. Gernsheimer T, Stratton J, Ballem PJ, Slichter SJ. Mechanisms of response to treatment in autoimmune thrombocytopenic purpura. *N Engl J Med.* 1989;320:974-80.
16. Olsson B, Andersson PO, Jernås M, Jacobsson S, Carlsson B, Carlsson LM, et al. T-cell-mediated cytotoxicity toward platelets in chronic idiopathic thrombocytopenic purpura. *Nat Med.* 2003;9:1123-4.

17. Imbach P, Kühne T, Signer E. Historical aspects and present knowledge of idiopathic thrombocytopenic purpura. *Br J Haematol.* 2002;119:894-900.
18. Ahn YS, Horstman LL. Idiopathic thrombocytopenic purpura: pathophysiology and management. *Int J Hematol.* 2002;76(Suppl 2):123-31.
19. Schwartz RS. Immune thrombocytopenic purpura--from agony to agonist. *N Engl J Med.* 2007;357:2299-301.
20. Shulman NR, Marder VJ, Weinrach RS. Similarities between known antiplatelet antibodies and the factor responsible for thrombocytopenia in idiopathic purpura. Physiologic, serologic and isotopic studies. *Ann N Y Acad Sci.* 1965;124:499-542.
21. van Leeuwen EF, van der Ven JT, Engelfriet CP, von dem Borne AE. Specificity of autoantibodies in autoimmune thrombocytopenia. *Blood.* 1982;59:23-6.
22. McMillan R, Wang L, Tani P. Prospective evaluation of the immunobead assay for the diagnosis of adult chronic immune thrombocytopenic purpura (ITP). *J Thromb Haemost.* 2003;1:485-91.
23. McMillan R, Lopez-Dee J, Bowditch R. Clonal restriction of platelet-associated anti-GPIIb/IIIa autoantibodies in patients with chronic ITP. *Thromb Haemost.* 2001;85:821-3.
24. Roark JH, Bussel JB, Cines DB, Siegel DL. Genetic analysis of autoantibodies in idiopathic thrombocytopenic purpura reveals evidence of clonal expansion and somatic mutation. *Blood.* 2002;100:1388-98.
25. Brighton TA, Evans S, Castaldi PA, Chesterman CN, Chong BH. Prospective evaluation of the clinical usefulness of an antigen-specific assay (MAIPA) in idiopathic thrombocytopenic purpura and other immune thrombocytopenias. *Blood.* 1996;88:194-201.
26. Stockelberg D, Hou M, Jacobsson S, Kutti J, Wadenvik H. Detection of platelet antibodies in chronic idiopathic thrombocytopenic purpura (ITP). A comparative study using flow cytometry, a whole platelet ELISA, and an antigen capture ELISA. *Eur J Haematol.* 1996;56:72-7.
27. Stasi R. Pathophysiology and therapeutic options in primary immune thrombocytopenia. *Blood Transfus.* 2011;9:262-73.
28. Zufferey A, Kapur R, Semple JW. Pathogenesis and therapeutic mechanisms in immune thrombocytopenia (ITP). *J Clin Med.* 2017;6:16.
29. Chauhan D. How ITP (immune thrombocytopenic purpura) can be treated in ayurveda?; (2023, December 16).
30. Kumar P, Charaniya R, Ghosh A, Sahoo R. Intravenous immunoglobulin responsive persistent thrombocytopenia after dengue haemorrhagic fever. *J Clin Diagn Res.* 2016;10:OD10-1.
31. Mitrakul C. Bleeding problem in dengue haemorrhagic fever: platelets and coagulation changes. *Southeast Asian J Trop Med Public Health.* 1987;18:407-12.
32. Srichaikul T, Nimmannitya S. Haematology in dengue and dengue haemorrhagic fever. *Baillieres Best Pract Res Clin Haematol.* 2000;13:261-76.
33. Srichaikul T. Disseminated intravascular coagulation in dengue haemorrhagic fever. *Southeast Asian J Trop Med Public Health.* 1987;18:303-11.
34. Lin CF, Lei HY, Liu CC, Liu HS, Yeh TM, Wang ST, et al. Generation of IgM anti-platelet autoantibody in dengue patients. *J Med Virol.* 2001;63:143-9.
35. Saito M, Oishi K, Inoue S, Dimaano EM, Alera MT, Robles AM, et al. Association of increased platelet-associated immunoglobulins with thrombocytopenia and the severity of disease in secondary dengue virus infections. *Clin Exp Immunol.* 2004;138:299-303.
36. Petäjä J. Inflammation and coagulation. An overview. *Thromb Res.* 2011;127(Suppl 2):S34-7.
37. Prashanth GP, Mugali SB. Persistent thrombocytopenia in dengue hemorrhagic fever. *Indian Pediatr.* 2011;48:737.
38. Kohli U, Saharan S, Lodha R, Kabra SK. Persistent thrombocytopenia following dengue shock syndrome. *Indian J Pediatr.* 2008;75:82-3.
39. Bhalla A, Bagga R, Dhaliwal LK, Sharma R, Varma S. Steroid responsive prolonged thrombocytopenia in dengue. *Indian J Med Sci.* 2010;64:90-3.
40. Mizutani H, Furubayashi T, Imai Y, Kashiwagi H, Honda S, Take H, et al. Mechanisms of corticosteroid action in immune thrombocytopenic purpura (ITP): experimental studies using ITP-prone mice, (NZW x BXSB) F1. *Blood.* 1992;79:942-7.
41. Agrawal S, Bhakuni H, Joshi RK. Ayurvedic management of idiopathic thrombocytopenic purpura: a case study. *Journal of Drug Delivery and Therapeutics.* 2019;9:508-10.
42. Savale P, Patil A, Hoge R. Therapeutic role of *Atrushkadi Kashaya* in the management of idiopathic thrombocytopenic purpura with reference to tiryak raktapitta. *Eur J Pharm Med Res.* 2021;8:167-9.
43. Rajshekar N, Shettar DR, Karlwad M. Understanding the concept of Raktapitta as idiopathic thrombocytopenic purpura (ITP) and vice versa. *J Ayurveda Integr Med Sci.* 2020;5:374-8.
44. Provan D, Stasi R, Newland AC, Blanchette VS, Bolton-Maggs P, Bussel JB, et al. International consensus report on the investigation and management of primary immune thrombocytopenia. *Blood.* 2010;115:168-86.
45. Purohit A, Aggarwal M, Singh PK, Mahapatra M, Seth T, Tyagi S, et al. Re-evaluation of need for bone marrow examination in patients with isolated thrombocytopenia contributors. *Indian J Hematol Blood Transfus.* 2016;32:193-6.
46. Altintas A, Ozel A, Okur N, Okur N, Cil T, Pasa S, et al. Prevalence and clinical significance of elevated antinuclear antibody test in children and adult patients with idiopathic thrombocytopenic purpura. *J Thromb Thrombolysis.* 2007;24:163-8.
47. Li HQ, Zhang L, Zhao H, Ji LX, Yang RC. Chronic idiopathic thrombocytopenic purpura in adult Chinese patients: a retrospective single-centered analysis of 1791 cases. *Chin Med J (Engl).* 2005;118:34-7.
48. Abbasi SY, Milhem M, Zaru L. A positive antinuclear antibody test predicts for a poor response to initial steroid therapy in adults with idiopathic thrombocytopenic purpura. *Ann Hematol.* 2008;87:459-62.
49. Neunert C, Terrell DR, Arnold DM, Buchanan G, Cines DB, Cooper N, et al. American Society of Hematology 2019 guidelines for immune thrombocytopenia. *Blood Adv.* 2019;3:3829-66.
50. Park YH, Kim DY, Kim S, Choi YB, Shin DY, Kim JS, et al. Management of immune thrombocytopenia: 2022 update of Korean experts recommendations. *Blood Res.* 2022;57:20-8.
51. Cuker A, Prak ET, Cines DB. Can immune thrombocytopenia be cured with medical therapy? *Semin Thromb Hemost.* 2015;41:395-404.

52. Mithoowani S, Gregory-Miller K, Goy J, Miller MC, Wang G, Noroozi N, et al. High-dose dexamethasone compared with prednisone for previously untreated primary immune thrombocytopenia: a systematic review and meta-analysis. *Lancet Haematol.* 2016;3:e489-96.
53. Imbach P, Barandun S, d'Apuzzo V, Baumgartner C, Hirt A, Morell A, et al. High-dose intravenous gammaglobulin for idiopathic thrombocytopenic purpura in childhood. *Lancet.* 1981;1:1228-31.
54. Schwab I, Nimmerjahn F. Intravenous immunoglobulin therapy: how does IgG modulate the immune system? *Nat Rev Immunol.* 2013;13:176-89.
55. Qin YH, Zhou TB, Su LN, Lei FY, Zhao YJ, Huang WF. The efficacy of different dose intravenous immunoglobulin in treating acute idiopathic thrombocytopenic purpura: a meta-analysis of 13 randomized controlled trials. *Blood Coagul Fibrinolysis.* 2010;21:713-21.
56. Bussel JB, Graziano JN, Kimberly RP, Pahwa S, Aledort LM. Intravenous anti-D treatment of immune thrombocytopenic purpura: analysis of efficacy, toxicity, and mechanism of effect. *Blood.* 1991;77:1884-93.
57. Scaradavou A, Woo B, Woloski BM, Cunningham-Rundles S, Ettinger LJ, Aledort LM, et al. Intravenous anti-D treatment of immune thrombocytopenic purpura: experience in 272 patients. *Blood.* 1997;89:2689-700.
58. Naithani R, Kumar R, Mahapatra M, Tyagi S, Saxena R. Efficacy and safety of anti-D for treatment of adults with immune thrombocytopenia. *Platelets.* 2009;20:525-7.
59. Hong F, Ruiz R, Price H, Griffiths A, Malinoski F, Woloski M. Safety profile of WinRho anti-D. *Semin Hematol.* 1998;35(1 Suppl 1):9-13.
60. Gaines AR. Acute onset hemoglobinemia and/or hemoglobinuria and sequelae following Rh(o)(D) immune globulin intravenous administration in immune thrombocytopenic purpura patients. *Blood.* 2000;95:2523-9.
61. Bao W, Bussel JB, Heck S, He W, Karpoff M, Boulad N, et al. Improved regulatory T-cell activity in patients with chronic immune thrombocytopenia treated with thrombopoietic agents. *Blood.* 2010;116:4639-45.
62. Kuter DJ, Bussel JB, Lyons RM, Pullarkat V, Gernsheimer TB, Senecal FM, et al. Efficacy of romiplostim in patients with chronic immune thrombocytopenic purpura: a double-blind randomised controlled trial. *Lancet.* 2008;371:395-403.
63. Bussel JB, Cheng G, Saleh MN, Psaila B, Kovaleva L, Meddeb B, et al. Eltrombopag for the treatment of chronic idiopathic thrombocytopenic purpura. *N Engl J Med.* 2007;357:2237-47.
64. Kuter DJ, Rummel M, Boccia R, Macik BG, Pabinger I, Selleslag D, et al. Romiplostim or standard of care in patients with immune thrombocytopenia. *N Engl J Med.* 2010;363:1889-99.
65. González-López TJ, Pascual C, Álvarez-Román MT, Fernández-Fuertes F, Sánchez-González B, Caparrós I, et al. Successful discontinuation of eltrombopag after complete remission in patients with primary immune thrombocytopenia. *Am J Hematol.* 2015;90:E40-3.
66. Mahévas M, Fain O, Ebbo M, Roudot-Thoraval F, Limal N, Khellaf M, et al. The temporary use of thrombopoietin-receptor agonists may induce a prolonged remission in adult chronic immune thrombocytopenia. Results of a French observational study. *Br J Haematol.* 2014;165:865-9.
67. Patel VL, Mahévas M, Lee SY, Stasi R, Cunningham-Rundles S, Godeau B, et al. Outcomes 5 years after response to rituximab therapy in children and adults with immune thrombocytopenia. *Blood.* 2012;119:5989-95.
68. Chugh S, Darvish-Kazem S, Lim W, Crowther MA, Ghanima W, Wang G, et al. Rituximab plus standard of care for treatment of primary immune thrombocytopenia: a systematic review and meta-analysis. *Lancet Haematol.* 2015;2:e75-81.
69. Deshayes S, Khellaf M, Zarour A, Layese R, Fain O, Terriou L, et al. Long-term safety and efficacy of rituximab in 248 adults with immune thrombocytopenia: Results at 5 years from the French prospective registry ITP-ritux. *Am J Hematol.* 2019;94:1314-24.
70. Ghanima W, Khelif A, Waage A, Michel M, Tjønnfjord GE, Romdhan NB, et al. Rituximab as second-line treatment for adult immune thrombocytopenia (the RITP trial): a multicentre, randomised, double-blind, placebo-controlled trial. *Lancet.* 2015;385:1653-61.
71. Li Y, Shi Y, He Z, Chen Q, Liu Z, Yu L, et al. The efficacy and safety of low-dose rituximab in immune thrombocytopenia: a systematic review and meta-analysis. *Platelets.* 2019;30:690-7.
72. Rodeghiero F. A critical appraisal of the evidence for the role of splenectomy in adults and children with ITP. *Br J Haematol.* 2018;181:183-95.
73. Wu JM, Lai IR, Yuan RH, Yu SC. Laparoscopic splenectomy for idiopathic thrombocytopenic purpura. *Am J Surg.* 2004;187:720-3.
74. Kojouri K, Vesely SK, Terrell DR, George JN. Splenectomy for adult patients with idiopathic thrombocytopenic purpura: a systematic review to assess long-term platelet count responses, prediction of response, and surgical complications. *Blood.* 2004;104:2623-34.
75. Boyle S, White RH, Brunson A, Wun T. Splenectomy and the incidence of venous thromboembolism and sepsis in patients with immune thrombocytopenia. *Blood.* 2013;121:4782-90.
76. Bisharat N, Omari H, Lavi I, Raz R. Risk of infection and death among post-splenectomy patients. *J Infect.* 2001;43:182-6.
77. Kim DS. Recent advances in treatments of adult immune thrombocytopenia. *Blood Res.* 2022;57:112-9.
78. Sree Subramania Ayurvedic Nursing Home. Best ITP treatment in India |Ayurvedic treatment of ITP. Sree Subramania Hospital, (2021, June 14).